

Mdm2 in Colon Carcinoma: gene amplification and correlation with protein expressions



Monirath Hav¹, Louis Libbrecht¹, Piet Pattyn², Marc Peeters³, Patrick Pauwels¹

Department of Pathology¹, Department of Abdominal Surgery²,
Department of Gastroenterology³, Ghent University Hospital, Belgium



BACKGROUND

New pharmacological agents targeting mdm2-p53 axis are now available. By blocking p53 degradation mediated by mdm2, wild-type p53 could restore its function and induce tumour cell apoptosis, especially when these cells express high p53 level as a result of chemo and/or radiation therapy. These molecules could be effective in the subset of patients whose mdm2 protein level is particularly high. To date, published studies on mdm2 status in colon carcinoma showed rather conflicting results. In this colon carcinoma study, we checked mdm2 status by immunohistochemistry (IHC) and Fluorescence In Situ Hybridization (FISH). FISH is less susceptible to interobserver variation. We correlated mdm2 gene amplification status with mdm2 protein expressions.

METHODS

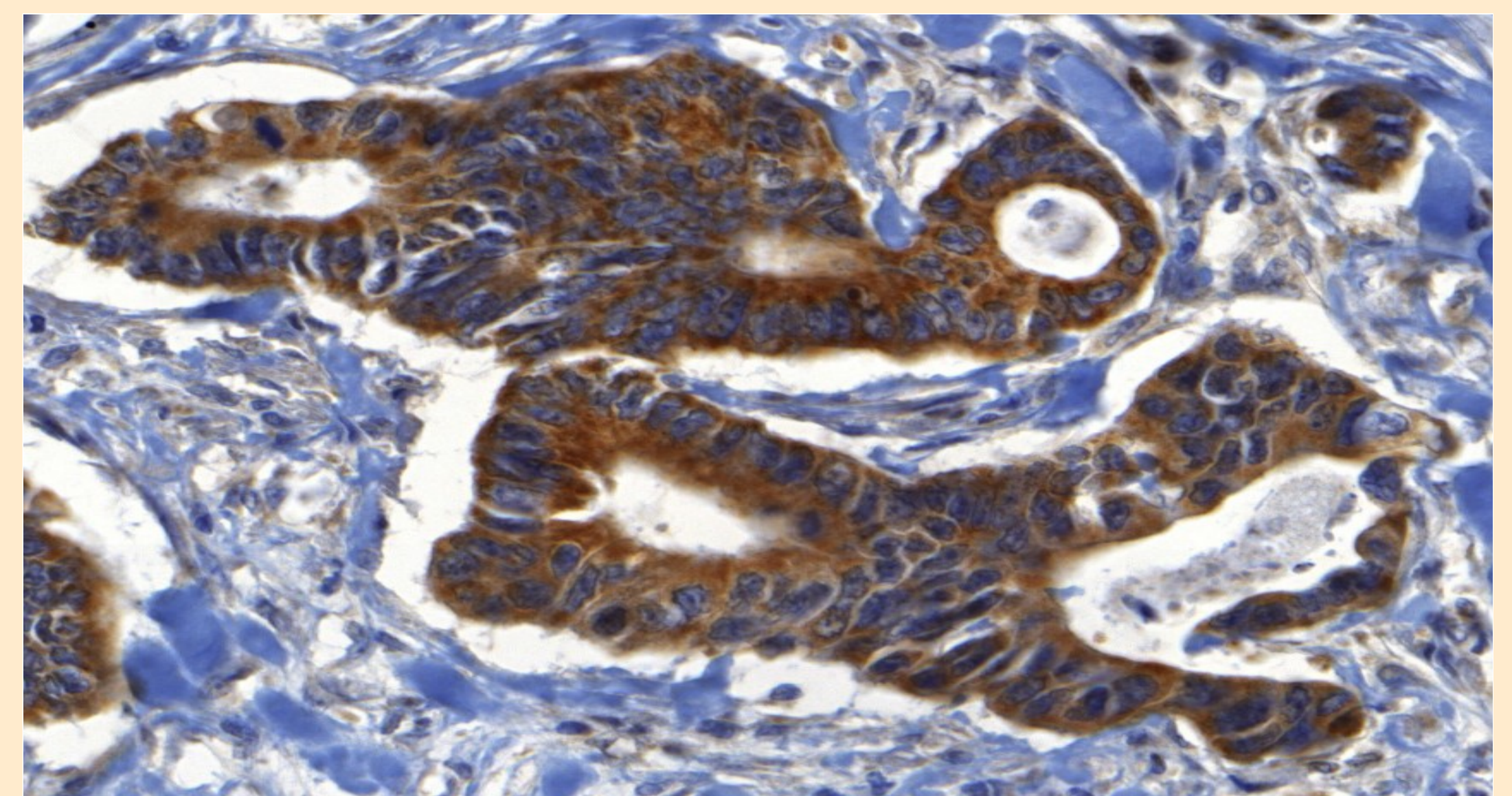
We examined 46 cases of invasive colon carcinoma. Mdm2 IHC and FISH were performed on paraffin-embedded sections. FISH was performed by using mdm2 gene probes and CEP12 probes. Mdm2 protein expressions were recorded based on staining pattern (cytoplasmic or nuclear), staining intensity (weak, moderate, or strong), and proportion of tumour cells stained. We then correlated mdm2 protein expressions with the FISH result.

RESULTS

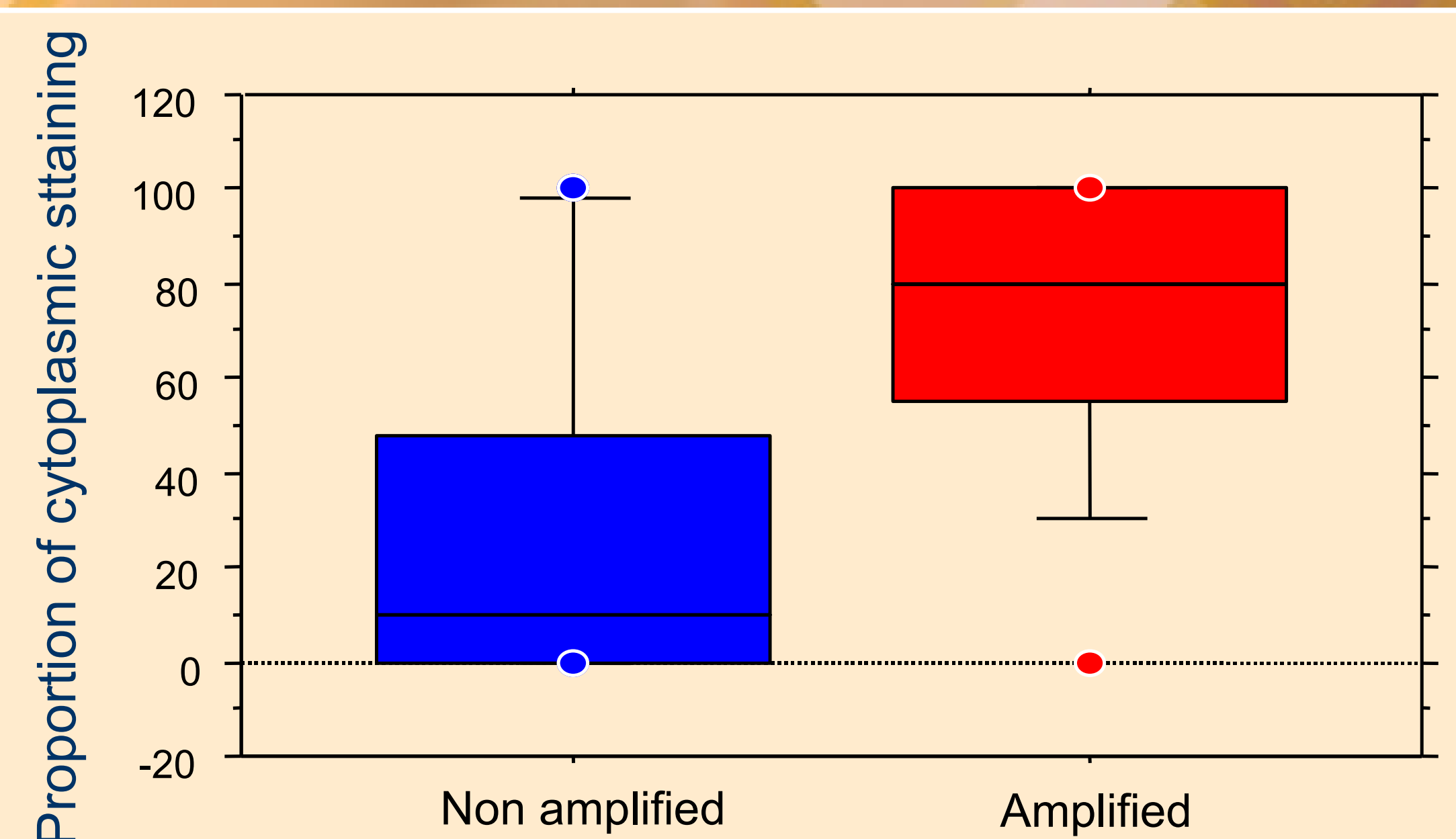
Of the 46 cases, 12 (26%) showed mdm2 amplification. Mdm2 nuclear positivity was seen in 19 cases (41%) and was very minimal in proportion with only one case having 100% of mdm2 nuclear expressions. There was no correlation between mdm2 gene amplification and mdm2 nuclear expressions. Cytoplasmic positivity, however, was observed in 29 cases (63%), and, interestingly, this staining pattern was seen more frequently in amplified cases (11 cases, 92%) than in non-amplified cases (18 cases, 55%). Therefore, we were able to demonstrate a strong correlation between mdm2 cytoplasmic expressions and mdm2 gene amplification ($p=0.0005$).



A case showing mdm2 gene amplification



A case showing only cytoplasmic expressions



Correlation between mdm2 gene amplification
and mdm2 cytoplasmic protein expressions

CONCLUSIONS

Contrary to most published results, we showed the presence of mdm2 amplification in 26% of invasive colon carcinoma cases. We also observed that there was a significant correlation between mdm2 gene amplification and cytoplasmic expressions regardless of the staining intensity.